



PATIENT

Mack Daniels

SPECIES

Canine

BREED

Boxer

SEX

Male Neutered

AGE

9 years

WEIGHT

82lbs

INTERPRETED BY

Maggie Machen Lamy,
DVM, DACVIM
(Cardiology)

IMAGING PERFORMED BY

Julia Bakker, DVM

HOSPITAL NAME

Orange Blossom
Veterinary Imaging

REFERRING VET

Dr. Destefano

INVOICE

46096

DATE

12/9/25

PRESENTING CLINICAL SIGNS

History: Presented following a syncopal episode.
ECG report (Idexx) sinus rhythm with isolated VPCs and ventricular bigeminy. Concern for ARVC.
Started Sotalol 40mg BID.

ECHOCARDIOGRAM FINDINGS

2D, m-mode, color flow and doppler imaging is available. Normal mitral valve leaflets with no prolapse into the left atrial lumen. Trace mitral regurgitation with a normal left atrial dimension. Normal velocity. Normal LV diameter with adequate myocardial function. The tricuspid valve appears normal with trace tricuspid regurgitation. Normal right atrial and ventricular diameter and morphology indicating no overt evidence of pulmonary arterial hypertension. The pulmonic and aortic valves are normal in morphology and mobility. Normal pulmonic and aortic outflow velocities with laminar flow. No aortic or pulmonic insufficiency. No pericardial or pleural effusion noted. No obvious cardiac masses.

CARDIAC CHART

CANINE CARDIAC PARAMETERS	MR VMAX (m/s)	TR VMAX (m/s)	LA/AO (Boon method)	LA/AO (Heart Base; Swe)	FS (%)	EF (%)	EPSS (cm)
NORMAL PARAMETER	4.5-5.5	<2.7	1.3	<1.6	28-40	40-100	<0.6
PATIENT	5.8	NM	NM	1.3	29	55	0.6
CANINE CARDIAC PARAMETERS	HR (BPM)	AV VMAX (m/s)	PV MAX (m/s)	BODY WEIGHT (kg)	LA 2D short axis Base view (cm)	LVIDd Avg; 2D and m-mode short axis (cm)	LVIDs Avg; 2D and m-mode short axis (cm)
NORMAL PARAMETER	50-100	0.7-1.7	0.7-1.6	BELOW	BELOW	BELOW	BELOW
PATIENT	NM	1.6	1.1	37.2	2.6	4.5	3.2
*Normal chamber parameters expressed as a mean value (SD)				3	1.27 (5.3)	2.46 (2.46)	1.36 (5.5)
BODY WEIGHT DEPENDENT PARAMETERS				5	1.40 (4.5)	2.74 (5.2)	1.60 (4.7)
*Note: All measurements based upon multi-modal images and methods. An average value is reported.				10	1.50 (3.8)	3.27 (3.5)	2.06 (3.1)
				15	1.83 (2.0)	3.71 (2.4)	2.43 (2.1)
				20	2.02 (1.9)	4.14 (2.2)	2.80 (2.0)
Adapted from June Boon, Veterinary Echocardiography, 1998				25	2.18 (2.4)	4.48 (2.9)	3.10 (2.5)
Rishniw M and Hollis NE, J Vet Intern Med 2000; 14:429-435				30	2.33 (3.3)	4.83 (3.9)	3.39 (3.4)
Hansson et al, Vet Rad and Ultrasound 2002				35	2.48 (4.3)	5.17 (5.0)	3.69 (4.5)
Bonagura et al. Echocardiography: principles of interpretation, Vet Clin North Am 15:1177, 1995				40	2.62 (5.2)	5.48 (6.1)	3.96 (5.4)
				50	2.88 (7.1)	6.07 (8.3)	4.46 (7.4)

INTERPRETATION OF THE FINDINGS & FURTHER RECOMMENDATIONS

The cardiac structure and function are overtly normal in this patient with no significant right heart enlargement appreciated. The left heart dimensions are normal, and the systolic function is considered adequate for a large breed dog. No significant valvular insufficiencies are seen. No additional issues are identified.

A history of ventricular arrhythmias in a boxer may suggest ARVC as the likely diagnosis. ARVC can occur with or without systolic dysfunction and structural issues; however, this should be monitored going forward for any progressive development. It is always reasonable to rule out other differentials for VPCs (AUS, tick titers, troponin, etc.); however, suspicion is low given the signalment of the patient. Unfortunately, there is always an elevated risk for collapse and sudden death in any arrhythmic patient, and even on medications this risk unfortunately still persists.



PATIENT

Mack Daniels

ARVC carries a HIGHLY variable prognosis, with some dogs able to remain asymptomatic for extended periods of time, and others developing exercise intolerance, syncope, and refractory arrhythmias/sudden death imminently.

SPECIES

Canine

Further comment on the arrhythmia (adequacy of the medication, etc.) cannot be made without follow up ECG/holter information. It is important to note that a holter monitor is the gold standard approach to screening patients with ventricular arrhythmias and should be considered prior to anesthesia. Continue Sotalol as previously prescribed.

BREED

Boxer

Fish oil supplementation is recommended for dogs with arrhythmias (1000mg of omega 3 and 6 once to twice daily as tolerated).

SEX

Male Neutered

Monitor at home for collapse, exercise intolerance, and/or lethargy. Anesthesia is not recommended until good arrhythmic control is achieved. Lifelong mild to moderate activity restriction is advised.

AGE

9 years

Even with good arrhythmic control, anesthetic risk is moderately elevated. Avoid ketamine, telazol, Dexdomitor (or other alpha-2 agonists) and acepromazine. Recommend having lidocaine CRI available for use in the event of worsening ventricular arrhythmias under anesthesia (CRI 50–75mcg/kg/min).

WEIGHT

82lbs

PLAN

Continue Sotalol as prescribed. Follow up for the arrhythmia should be dictated by the holter report.

INTERPRETED BY

Maggie Machen Lamy,
DVM, DACVIM
(Cardiology)

Recheck echocardiogram is recommended every 6-12 months, sooner if any clinical signs arise.

IMAGING PERFORMED BY

Julia Bakker, DVM

HOSPITAL NAME

Orange Blossom
Veterinary Imaging

REFERRING VET

Dr. Destefano

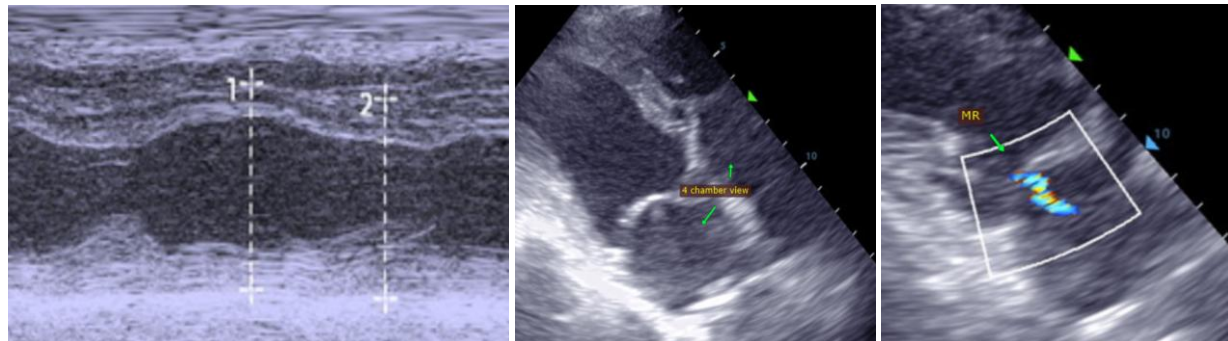
INVOICE

46096

DATE

12/9/25

IMAGES



The information and recommendations provided are based on the images presented by the referring veterinarian. No evaluation can be communicated regarding pathology that was not visible in the image/video clips provided.

Thank you for this referral. This report was generated using transcription software, and minor dictation errors may be present. If the clinical or image interpretation does not parallel your findings or if I can be of any further assistance, please contact me.

Maggie Machen Lamy, DVM
Diplomate of the American College of Veterinary Internal Medicine (Cardiology)
info@sonopath.com